

**2021 ASCO**<sup>®</sup>  
ANNUAL MEETING

**FIRST IN HUMAN CLINICAL TRIAL  
WITH CAN-3110 (ICP-34.5  
EXPRESSING HSV-1 ONCOLYTIC  
VIRUS) IN PATIENTS WITH  
RECURRENT HIGH-GRADE GLIOMA**

---

E. Antonio Chiocca, MD PhD

Department of Neurosurgery

Brigham and Women's Hospital

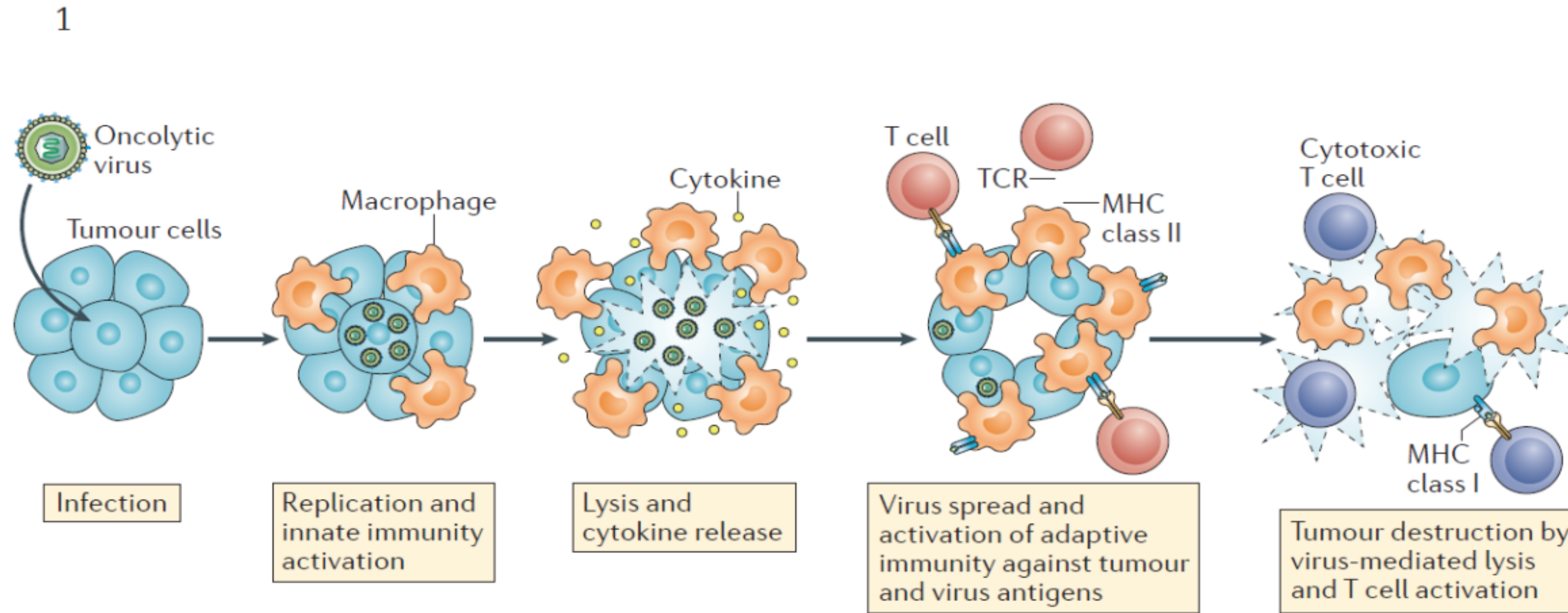
Harvard Medical School

June 4, 2021



# Oncolytic virus mechanisms of tumor killing:

- A) infection/replication with direct cytotoxicity followed by
- B) Immune cell Activation



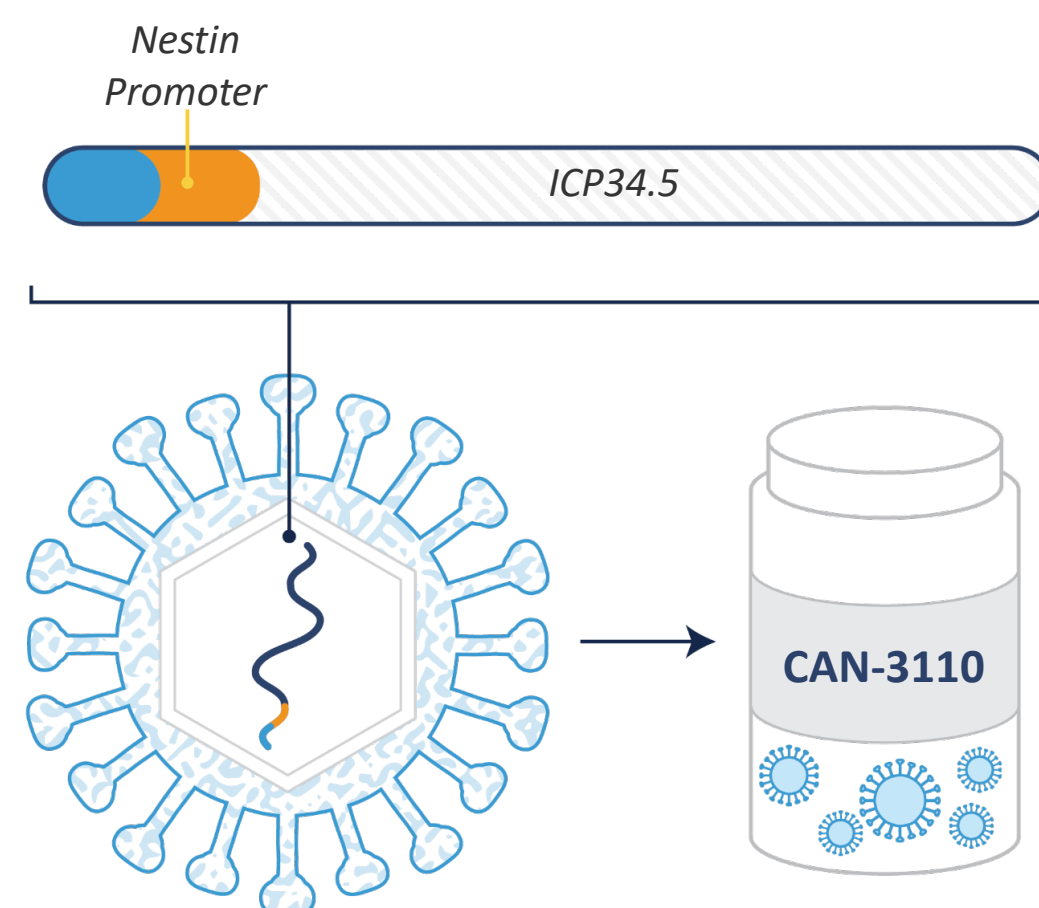
Nature Reviews | **Clinical Oncology**

*Peruzzi and Chiocca, 2018*

# CAN-3110 (formerly known as rQNestin34.5v.2, Nakashima et al, 2020)

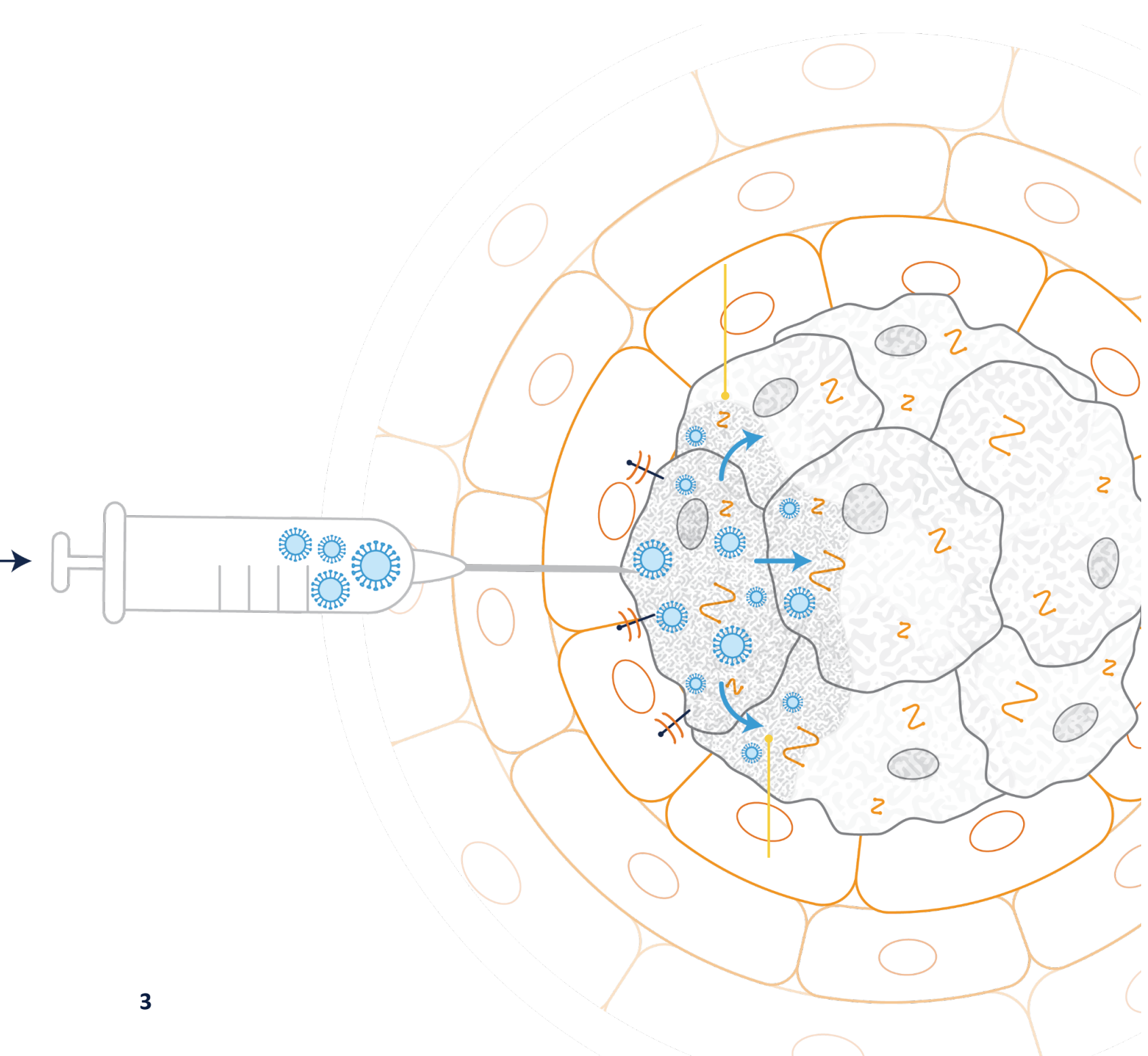
## HSV-1 engineered for immunogenic potency and specificity

- ICP34.5-null viruses have shown safety but replicate poorly
- CAN-3110: ICP34.5 expression under control of Nestin promoter
  - Nestin overexpressed in gliomas
  - Improves replication
  - Provides tumor-specific oncolytic activity



## Designed for Safety

- Disruption of ICP6 limits virus replication to dividing cells or cells with p16 tumor suppressor pathway defects
- Remains sensitive to anti-herpetic drugs
- Nestin provides tumor specificity in a range of other indications



3

# Oncolytic Herpesvirus Study in Recurrent High-Grade Glioma CAN-3110 Phase 1 Study

## Study Design

- Direct intra-tumoral injection
- Open label with CAN-3110
- 3 x 3 Dose-escalation design  
1x10<sup>6</sup> to 1x10<sup>10</sup> PFU in half-log increments

## Patient Population

- Recurrent high-grade glioma
- Lesions ≥ 1.0 cm

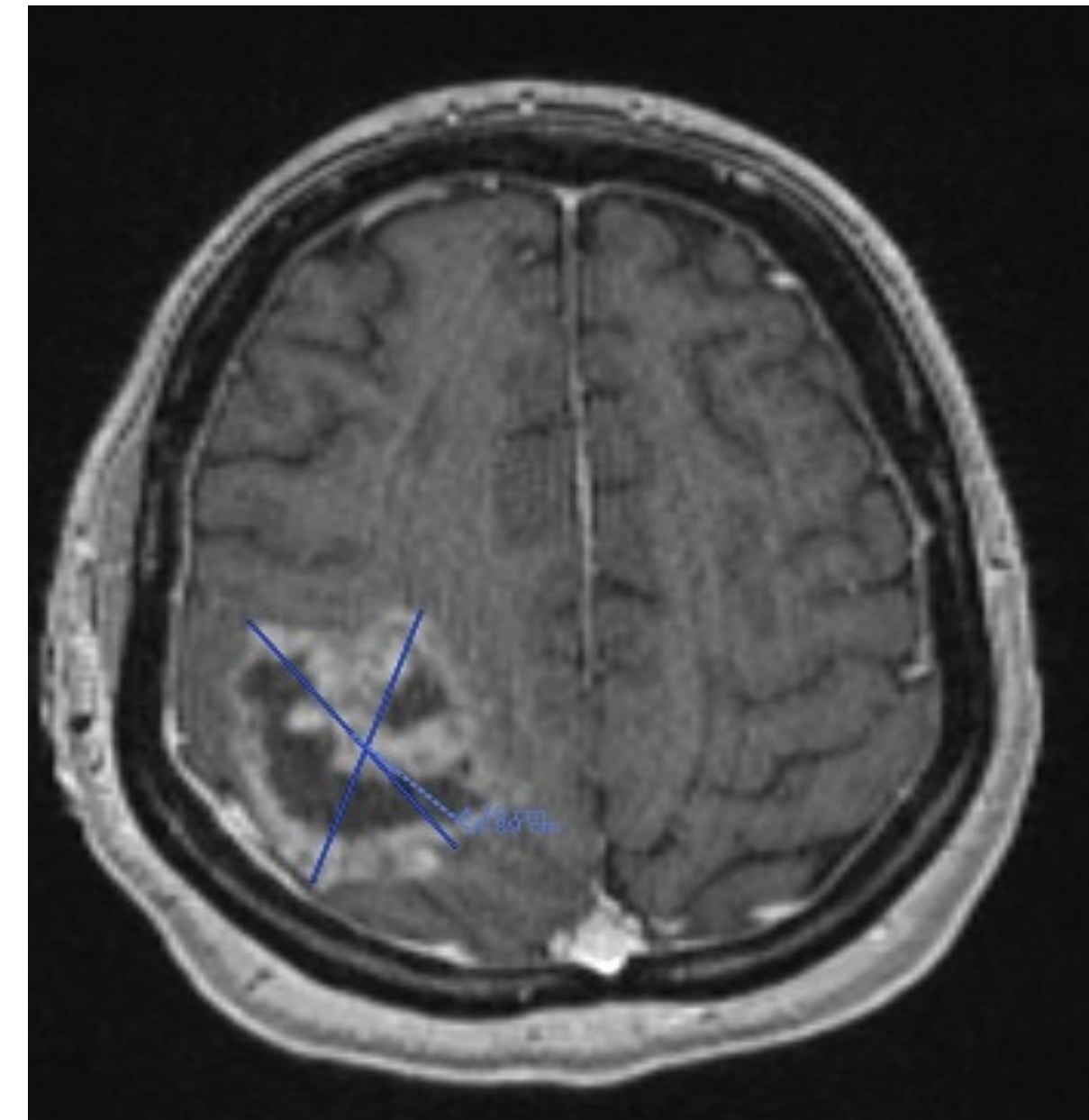
## Endpoints – Primary

- Safety
- Determine maximum tolerated dose

## Endpoints - Other

- Immunological biomarkers
- MRI alteration of permeability and flow at injection site
- MRI assessment of disease and PFS

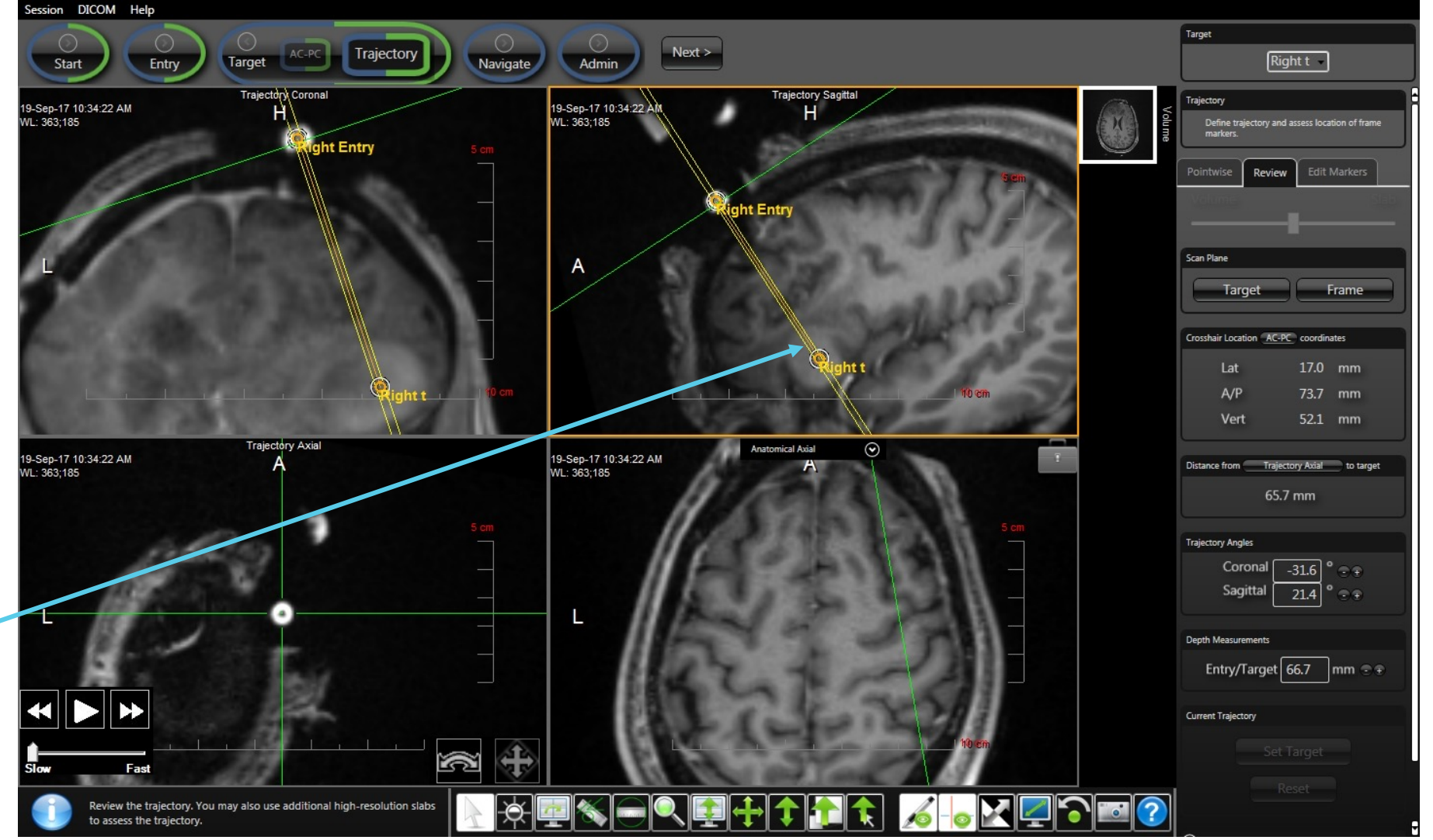
Recurrent HGG



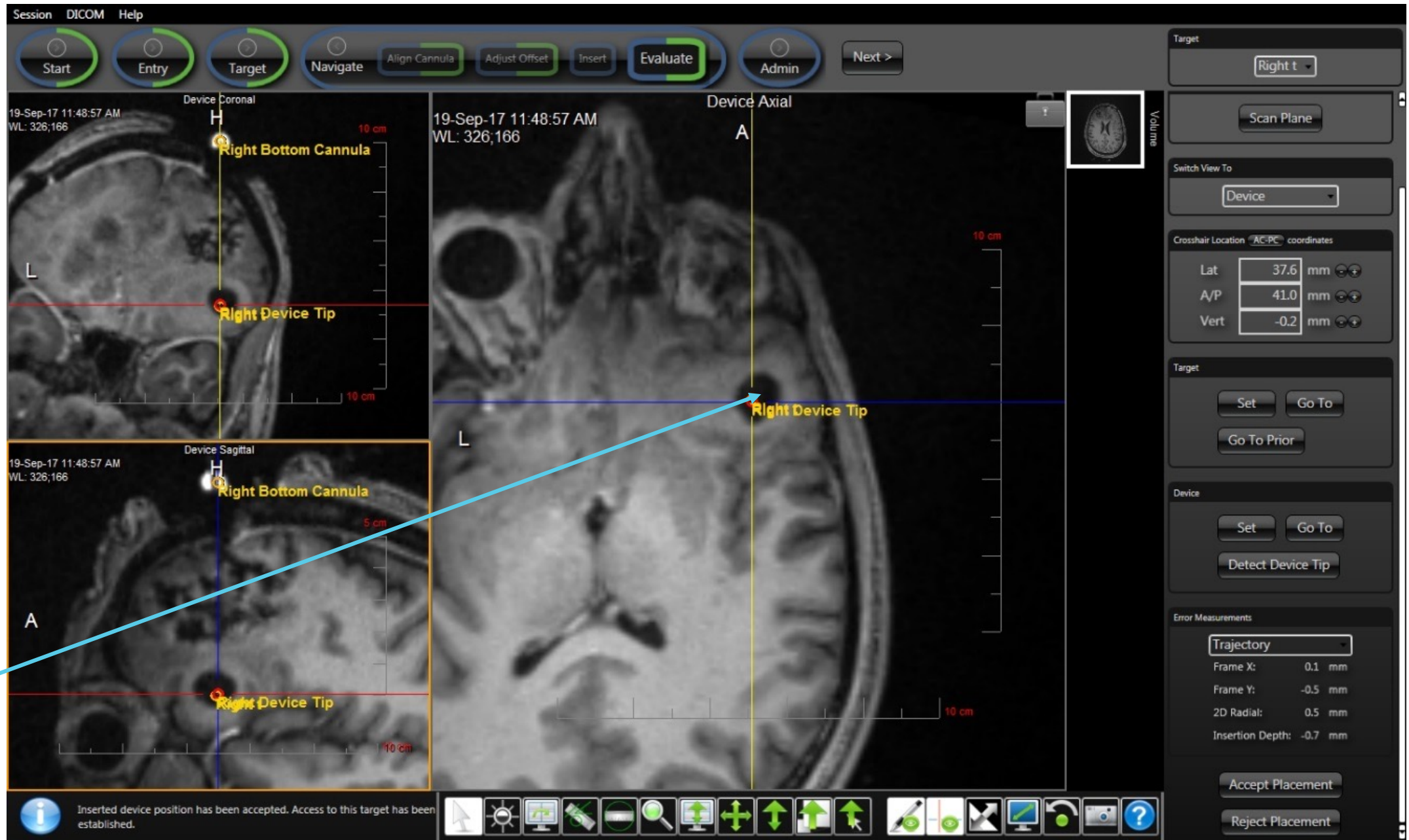
# Modality of injection

- Intraoperative MRI
- Stereotactic injection
- Injection vs. CED

Planned needle track injection into recurrent GBM



Intraoperative Post-injection MRI  
 Black hole: fluid containing HSV1  
 Day 1 post injection MRI  
 demonstrated reabsorbed fluid



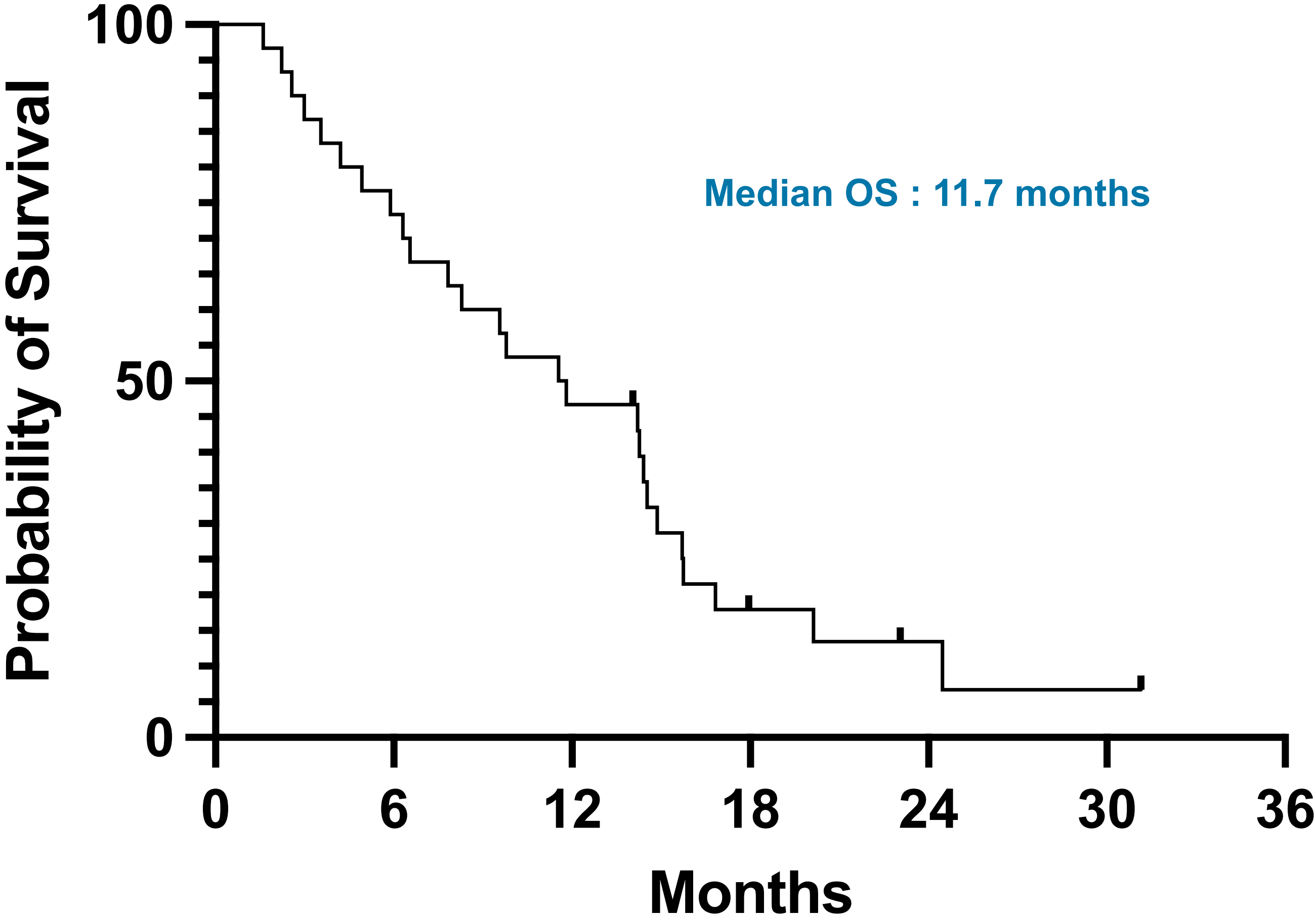
# Demographics

Number of patients: 30		
	n	%
<b>AGE</b>		
Median age	56	
Range	30-74	
<b>SEX</b>		
Female	13	43.3
Male	17	56.7
<b>KPS (Baseline)</b>		
Median KPS	90	
<b>MGMT</b>		
Methylated	9	30.0
Unmethylated	19	63.3
Unknown	2	6.7
<b>IDH</b>		
Wild type	25	83.3
Mutant	5	16.7
Unknown	0	0.0
<b>TUMOR</b>		
Grade 3	4	13.3
Grade 4	26	86.7
Other	0	0
<b>MULTI-FOCAL/ -CENTRIC TUMORS</b>		
	5	16.7
<b>TUMOR VOLUME</b>		
Range (mm <sup>3</sup> )	357.4 – 54,036.1	
Median (mm <sup>3</sup> )	8,153.6	
SD	17,397.15	
Mean (mm <sup>3</sup> )	15,338.8	

# Safety data (all related AE and SAE)

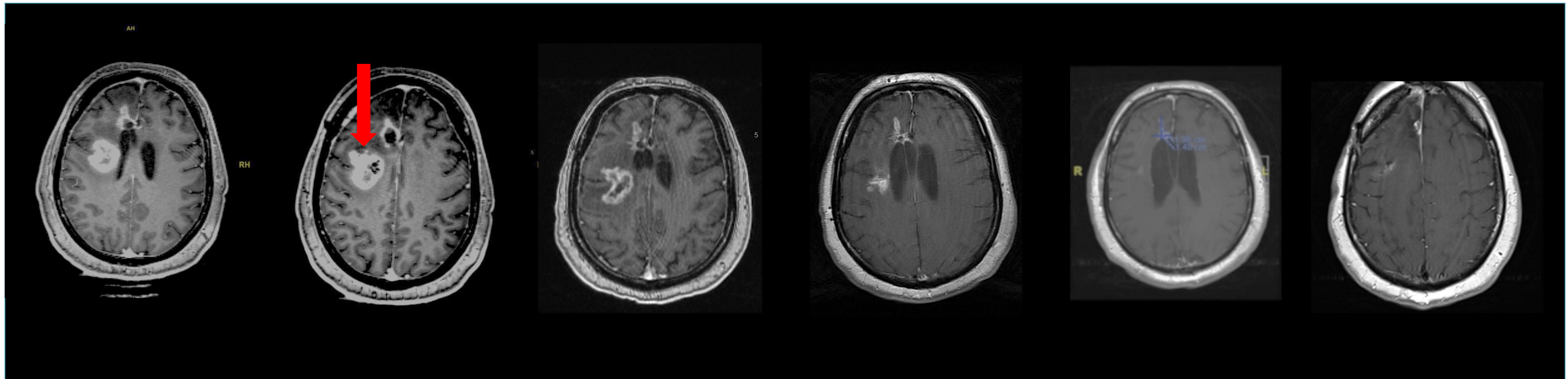
Category	CTC Grade 1 (Mild)	CTC Grade 2 (Moderate)	CTC Grade 3 (Severe)	CTC Grade 4 (Severe)
<b>BLOOD AND LYMPHATIC SYSTEM DISORDERS</b>				
Low Eosinophil Count	1			
<b>GENERAL DISORDERS AND ADMINISTRATION SITE CONDITIONS</b>				
Fatigue	1			
<b>INVESTIGATIONS</b>				
Alanine Aminotransferase Increased	1			
Lymphocyte Count Decreased	1			
Platelets Count Decreased	1			
<b>MUSCULOSKELETAL AND CONNECTIVE TISSUE DISORDERS</b>				
Muscle Weakness – Lower Limb	1			
<b>NERVOUS SYSTEM DISORDERS</b>				
Cerebral Hematoma			1	
Edema Cerebral	1	2		
Expressive Aphasia	1			
Headache		1		
Nervous System Disorder, other Speech		1		
Speech Difficulty		1		
<b>PSYCHIATRIC DISORDERS</b>				
Anxiety		1		

# Survival



# Single agent activity of CAN-3110 in recurrent HGG

## Clinical effect on injected tumor and uninjected tumor



Baseline

Day 0

Black hole within tumor  
image is injection site  
 $10^6$  PFU dose

Day 56

Reduction in contrast area  
with no additional treatment

Day 111

Patient back to work

Day 168

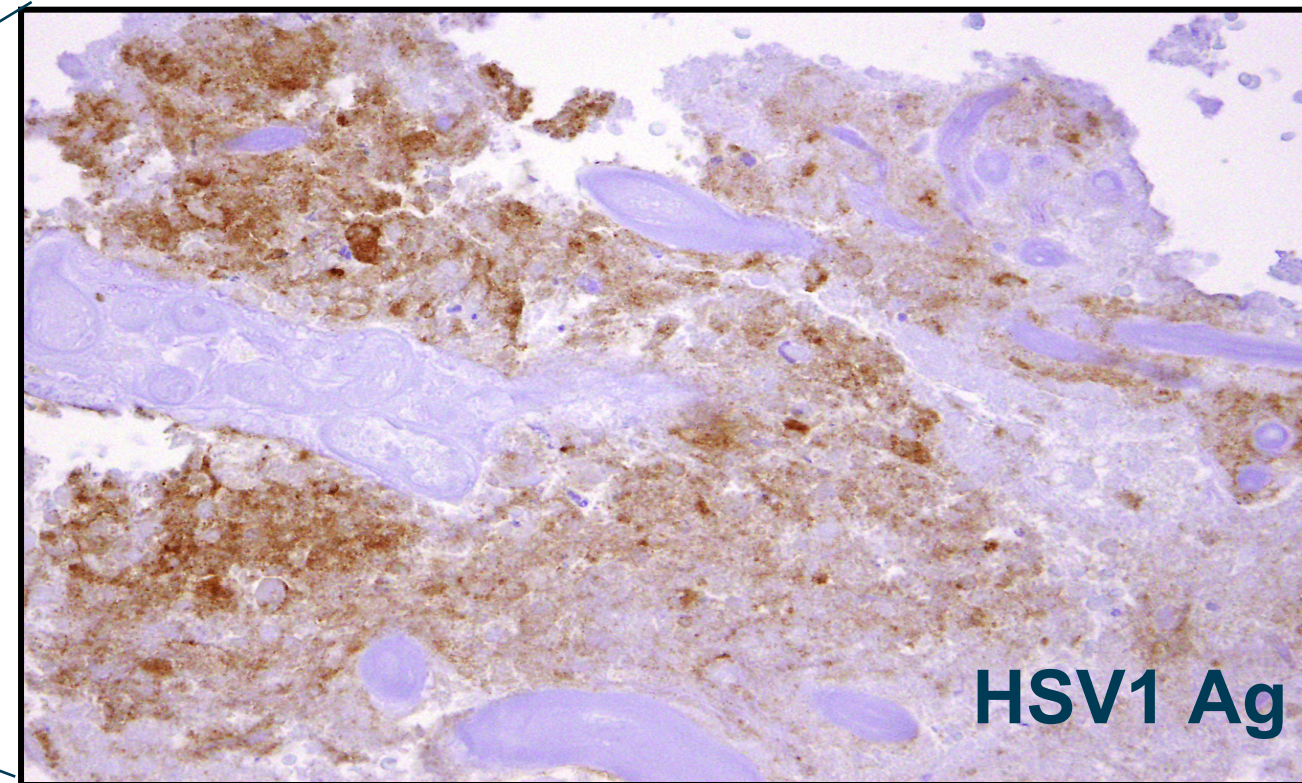
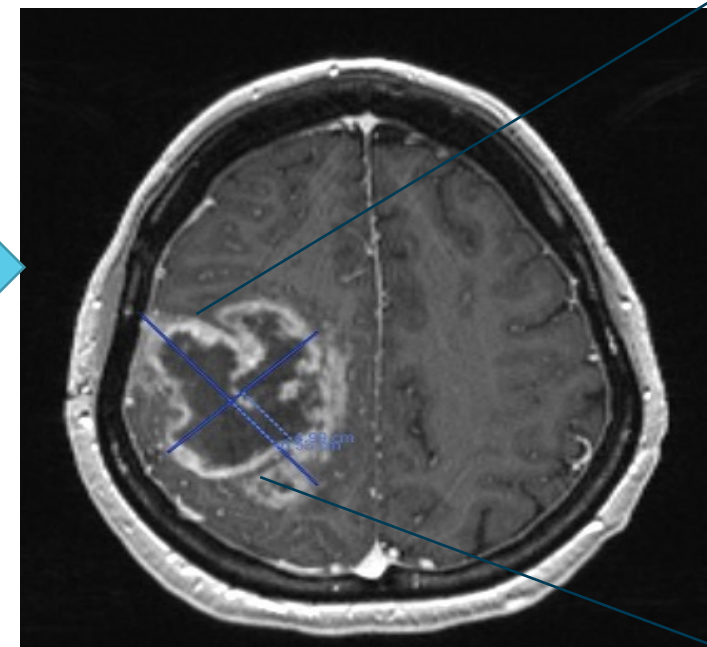
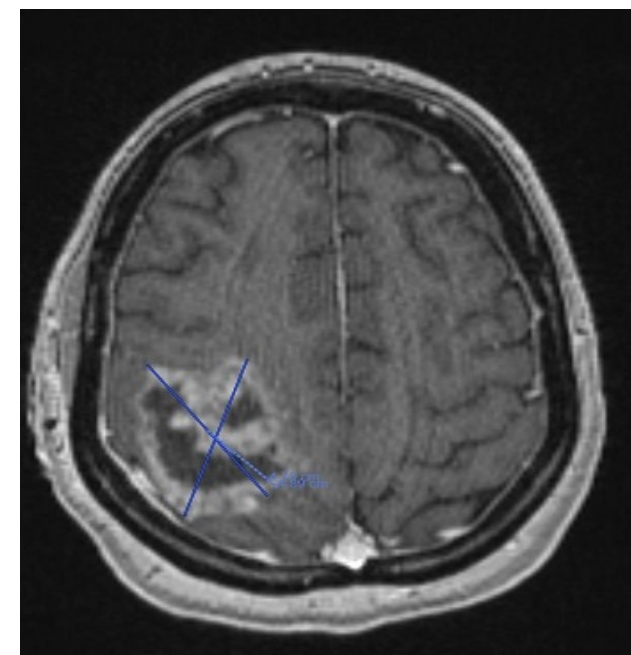
Day 280

*56 YOM, IDH wild-type, MGMT partially methylated, right frontal mesial lesion initially treated with GTR, chemoradiation. Recurrences at two sites.*

# Evidence for persistent HSV antigen, viral replication and T cell infiltration in humans after CAN-3110 treatment

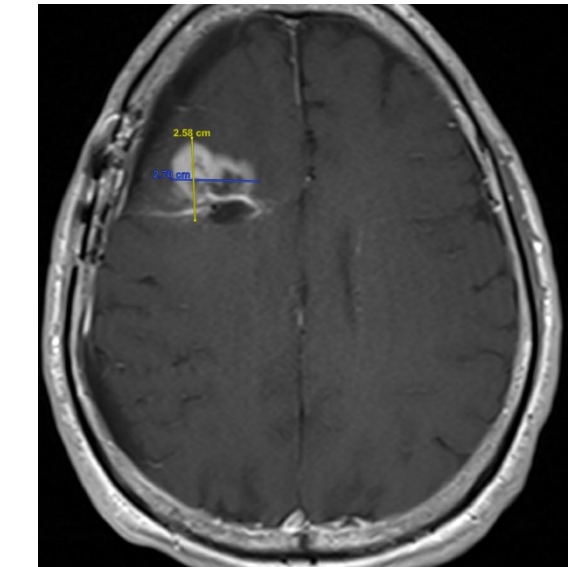
## Patient A

(6 weeks post-HSV 10e6 pfus)

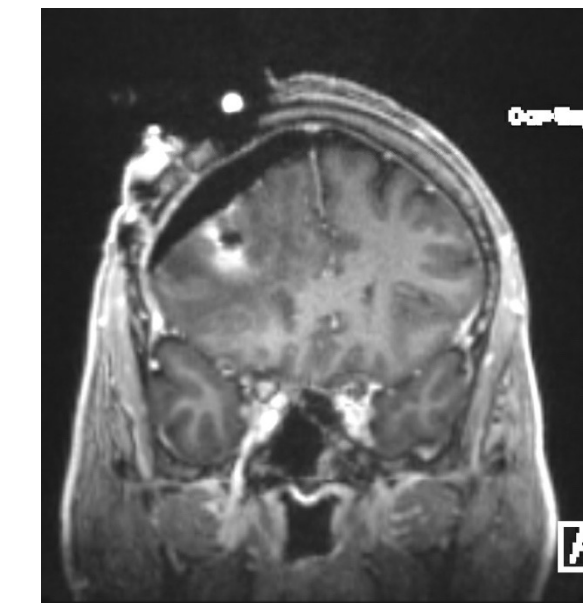


HSV1 Ag

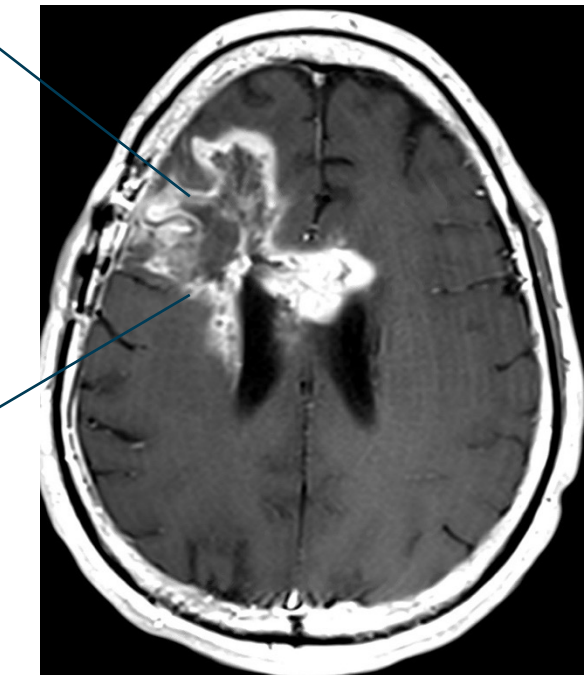
Preoperative



Intraoperative injection

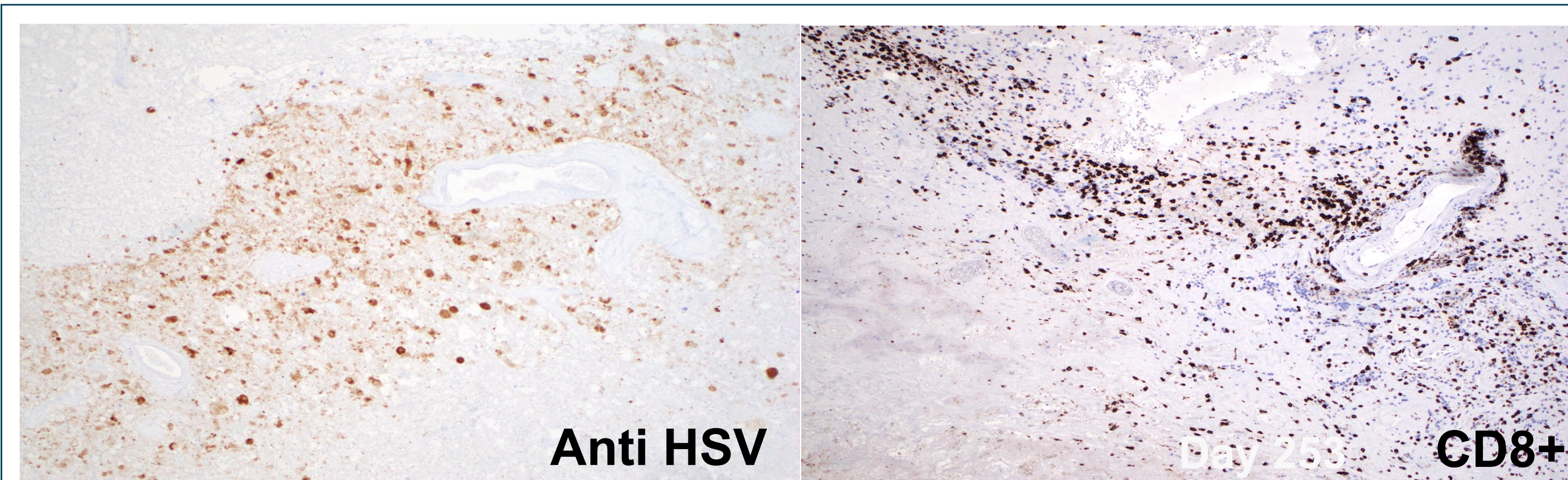


Recurrence



## Patient B

(9 mo post-HSV 10e9 pfus)

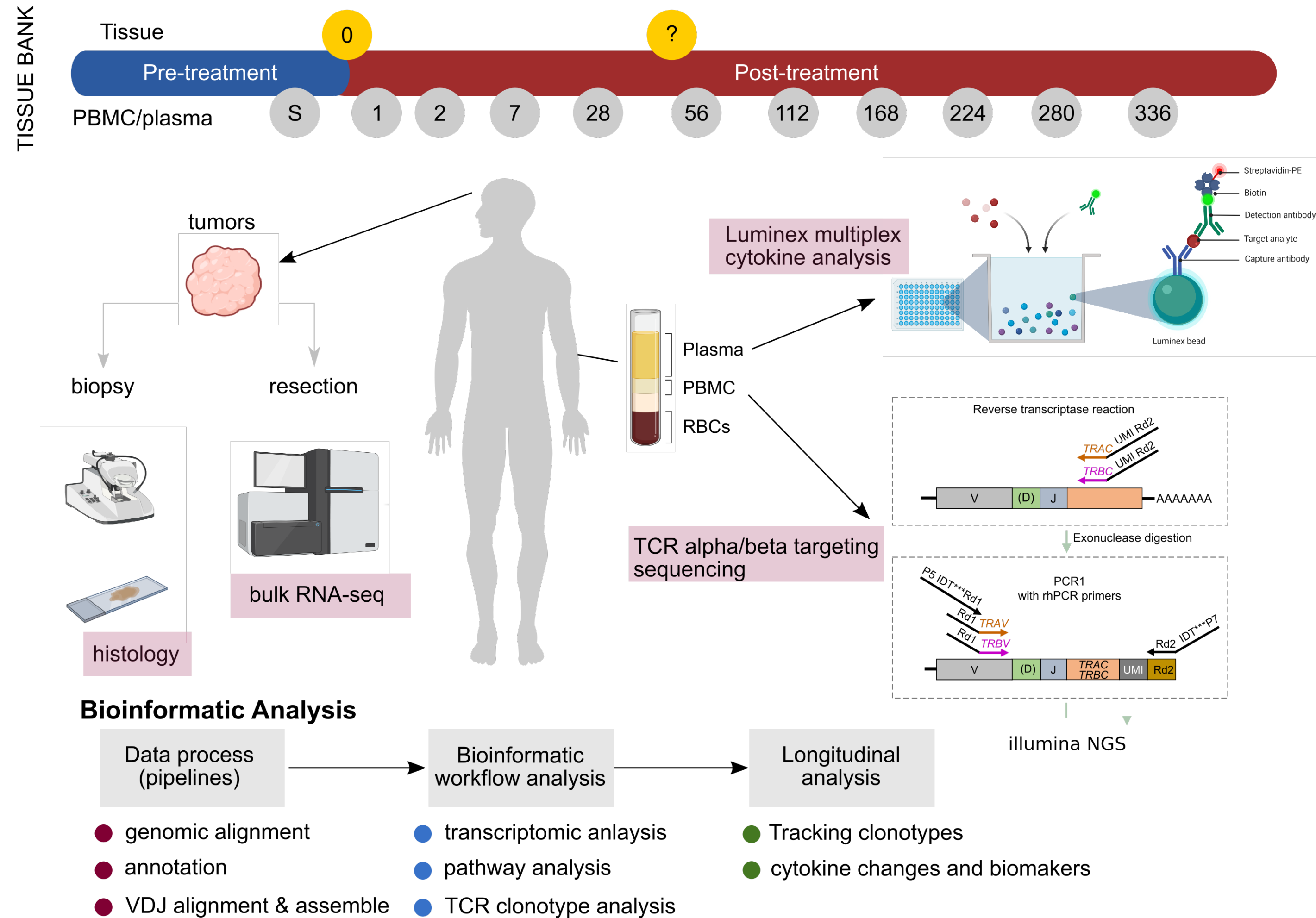


Anti HSV

Day 25

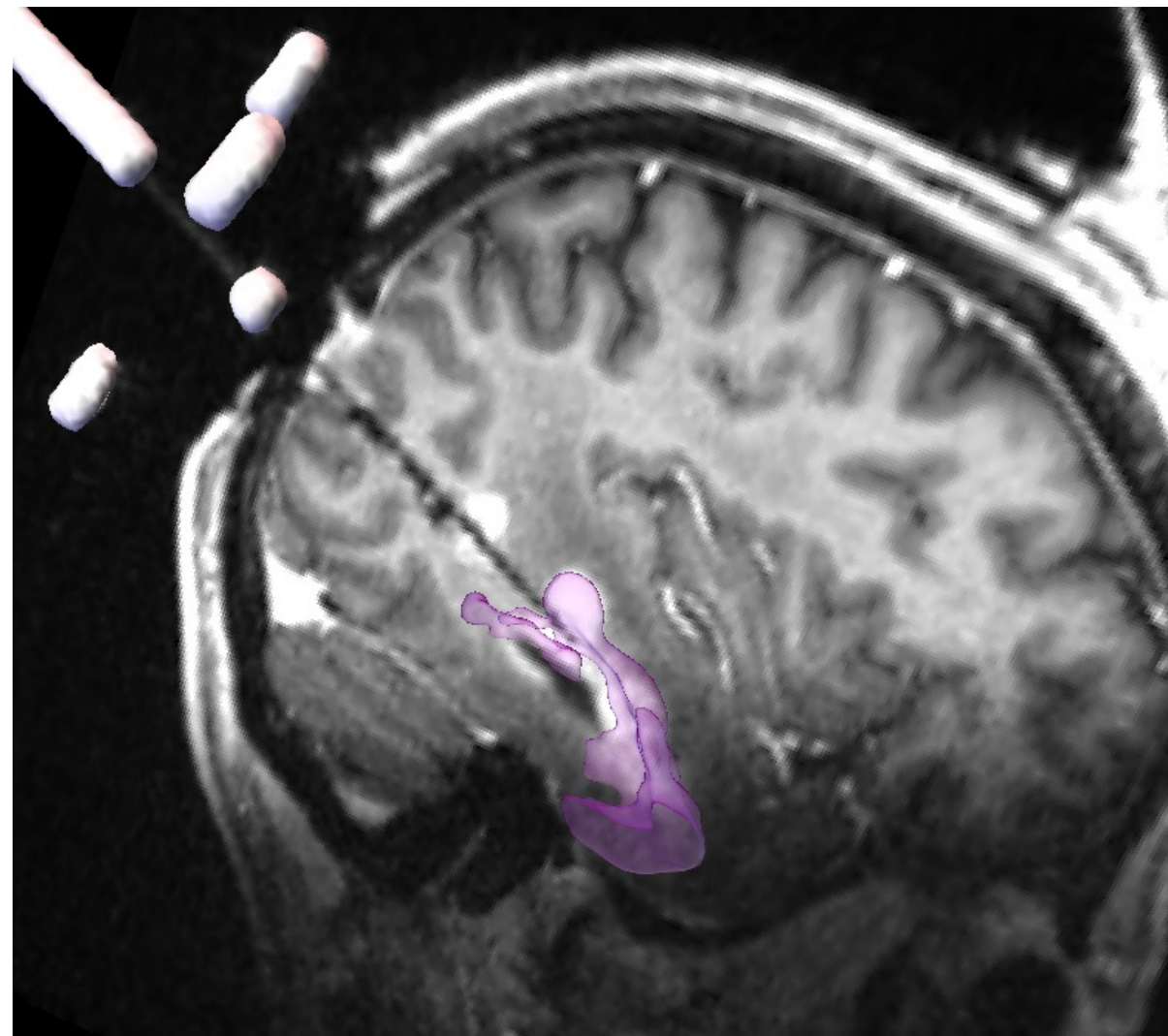
CD8+

# Ongoing sample analysis

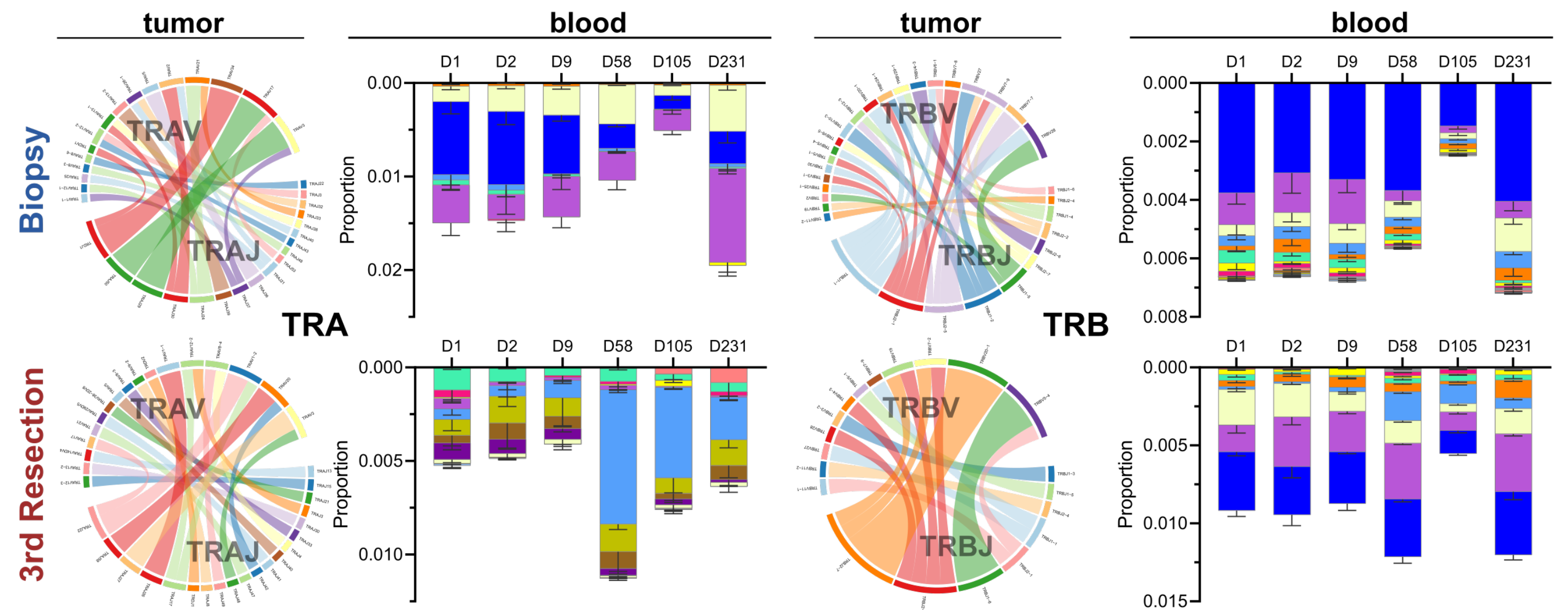


# Ongoing biomarker studies

## Brain volumetric assessment during CAN-3110 injection

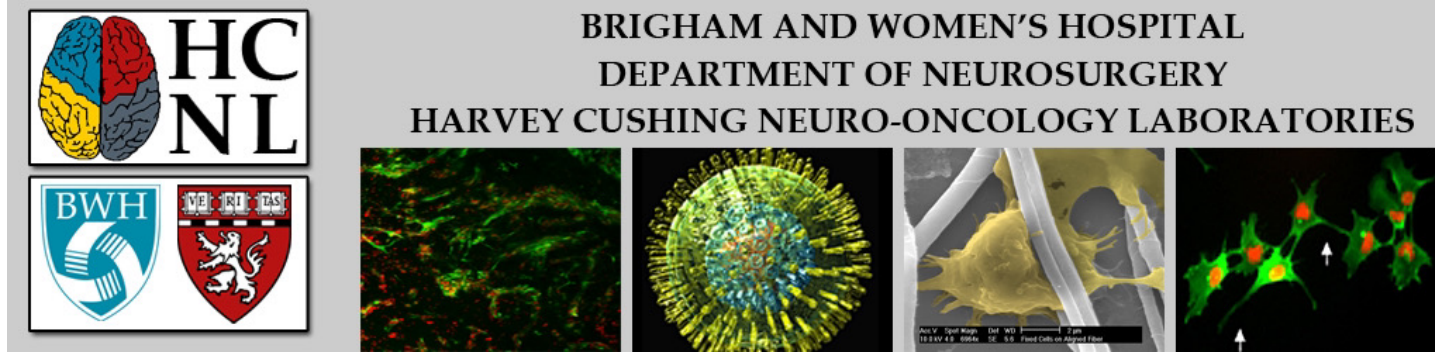


Proportion of unique TCR alpha and beta clonotypes in tumor infiltrating lymphocytes shared with PBMCs



# Conclusions

- GBM injection of CAN-3110, a new oncolytic HSV1 that expresses the ICP34.5 neurovirulence factor, is well tolerated up to  $10E10$  pfus
- There is evidence of HSV1 antigen persistence even after several months
- There is a brisk inflammatory infiltrate in GBMs even after several months (“cold” to “hot”)
- Survival data is preliminary but encouraging
- Additional scientific analysis including single cell analysis, bulk RNAseq, TCR sequencing and tissue immunophenotyping ongoing



## Current group:

**Hiroshi Nakashima, PhD**

**Marco Mineo, PhD**

**Raziye Piranloglu, PhD**

**Alex Ling, PhD**

**Eleni Panagioti, PhD**

**Naoiuki Shono, MD PhD**

**Himanshu Soni, PhD**

**Shikha Saini PhD**

**Junfeng Liu, MD PhD**

**Sean Lawler, PhD and all past postdocs and students**

### Funding:

**NINDS (NIH) U01 translational program**

**NCI (NIH) P01CA163205, R01NS110942,**

**P01CA236749**

**ACGT gene therapy preclinical development**

### CRCs:

**James Grant**

**Abigail Zhang**

**Grace Park**

**Leah Seften**

**Kyla Truman**

**Collaborators: Gordon Freeman, PhD, DFCI; David Knipe, PhD, HMS; Xandra Breakefield, MGH, Patrick Wen, MD, David Reardon, MD, Arlene Sharpe, MD PhD, Kai Wucherpennig, PhD, Keith Ligon, MD PhD; Isaac Solomon, MD PhD; Mike Caligiuri, MD PhD, Balveen Kaur, PhD, Joe Glorioso, PhD, Paola Grandi, PhD, Marine Lamfers, PhD, Vijay Kuchroo, PhD, Ana C. Anderson, PhD and many many others; Estuardo Aguilar-Cordova, Laura Aguilar, Francesca Barone, David Krisky (Candel Therapeutics, Inc., former Advantagene Inc.)**